The Use of Mesenchymal Stem Cells in the Treatment of Talar Avascular Necrosis

A Case Study

Purpose

The authors present a case of post-traumatic talar avascular necrosis (AVN) with ankle joint ankylosis treated with ankle joint diastasis and subtalar joint (STJ) fusion augmented with the application of mesenchymal stem cells and other orthobiologics.

Revascularization of the talus by utilizing the highly vascular calcaneus through a STJ arthrodesis has not been previously described in the literature to the authors' knowledge.

Figure 1

Figure 2



Figure 3: Compression of Subtalar Joint

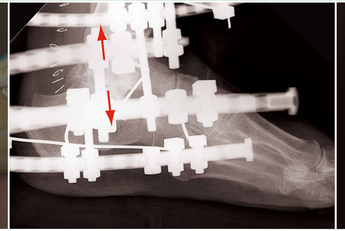

Figure 4: Distraction of Ankle Joint

Figure 5

Case Study

A 49-year-old female presented to the clinic complaining of severe ankle and rearfoot pain. The patient had limited ankle joint range of motion (ROM) with pain noted throughout. She did not recall any significant trauma to the lower extremity but stated she had "rolled her ankle" at work several months previously. She also exhibited pain with ROM of the STJ. Conservative treatment including corticosteroid injections and bracing subsequently failed. Pre-operative radiographs and MRI reveal AVN of the talus affecting over 80% of the talar body (**Figure 1 and 2**). After thorough discussion of possible treatment options, the patient wished to proceed with the treatment plan, which consisted of STJ arthrodesis and ankle joint diastasis utilizing a multi planar ring external fixator (Tru/Lok, Orthofix).

Cartilage resection was carried out through a small incision at the level of the posterior facet of the STJ utilizing osteotomes. The subchondral bone was fenestrated to augment the arthrodesis. All necrotic bone was excised by curettage. Application of mesenchymal stem cells (Trinity, Orthofix), bone marrow aspirate and cancellous bone chips were then packed within the fusion site and a multiplanar ring external fixator was applied for STJ arthrodesis compression and ankle joint diastasis (**Figure 3 & 4**).

The patient was allowed to immediately weight bear within the multiplanar ring external fixator. Following external fixator removal and ankle arthroscopy the patient achieved pain free full range of motion at the ankle joint at 10 months post op with only mild discomfort after 6 hours of weightbearing activity. At the time of external fixation removal a lateral ankle joint stabilization procedure was also performed. Radiographs confirmed revascularization of the talus and successful STJ fusion (**Figure 5**).

Literature Review

Osteonecrosis of the talus is a relatively rare condition, often occurring secondary to trauma at the ankle, but also as a result of chronic alcoholism, sickle cell disease, and prolonged corticosteroid use.[1] Hawkins was the first to describe this phenomenon in 1970 according to the amount of displacement, as well as interruption of the vascular supply.[2] Atraumatic osteonecrosis of the talus is much less common than post-traumatic avascular necrosis, with a previously described incidence of 2% of all talar osteonecroses by Delanois et al.[3]

Although post-traumatic talar avascular necrosis has been well documented, the exact mechanism of atraumatic osteonecrosis is not well described in the literature. Surgical treatment for osteonecrosis of the talus has been previously described, including core decompression, tibiotalar fusion, and talectomy with tibiocalcaneal fusion.[1,4] It is not clear within the literature which treatment is preferred for atraumatic versus traumatic osteonecrosis of the talus. The use of stem cells to treat osteonecrosis has been discussed as a potential treatment, however to the authors' knowledge this is the first published report of the use of mesenchymal stem cells as a treatment for osteonecrosis of the talus.[5]

Discussion

With the explosion of orthobiologics into the field of orthopedics, the use of autografts and subsequent donor site morbidity is becoming a thing of the past. It is hoped that this approach to talar AVN can give patients and surgeons an alternative to talectomy with tibiocalcaneal fusion and the sequelae caused by such treatments. By utilizing the vast blood supply of the calcaneus through a STJ arthrodesis, the talus has been shown to revascularize and preserve normal articular function at the ankle joint. Ankle diastasis has been shown efficacious in the treatment of mild to moderate degenerative joint disease and allows increased hydrostatic forces within the ankle joint during talar revascularization.

References:

1. Mont MA, Schon LC, Hungerford MW, Hungerford DS. *Avascalar necrosis of the talus treated core decompression.* J Bone Joint Surg Am. 1996 Sept;78(5):827-830.
2. Hawkins LG. *Fractures of the neck of the talus.* J Bone Joint Surg Am. 1970;(52):991-1002.
3. Delanois RE, Mont MA, Yoon TR, Mizell M, Hungerford DS. *Atraumatic osteonecrosis of the talus. Kitaoka HB, Patzer GL. Arthrodesis for the treatment of arthrosis of the ankle and osteonecrosis of the talus.* J Bone Joint Surg Am. 1998 Oct;80(10):1553.
4. Dennison MG, Pool RD, Simonis RB, Singh BS. *Tibiocalcaneal fusion for avascular necrosis of the talus.* J Bone Joint Surg Br. 2001 Mar;83(2):199-203.
5. Lee K, Chan CK, Patil N, Goodman SB. *Cell therapy for bone regeneration-Bench to bedside.* J Biomed Mater Res B Appl Biomater. 2008 Sep 5.

Key Contributors:
Edgardo R. Rodriguez, DPM Clinical Instructor
Director: Chicago Foot & Ankle Deformity Correction Center

Shawn Hatfield DPM PGY-3

Justin T. Albright DPM PGY-3

Affiliation(s): St. Joseph Hospital/North Chicago DVAMC PM&S-36 Residency Program

Category: Rearfoot & Ankle Reconstruction
Type of Submission: Institution
Format: Case Study

Presented: American College of Foot & Ankle Surgeons Scientific National Meeting 2009

Resurrection Health Care

Podiatric Surgical Residency Program
St. Joseph Hospital/North Chicago DVAMC PM&S-36
Program Director
Frank W. Zappa, DPM

©2009 Resurrection Health Care. All Rights Reserved.