Advantages of Locking Plate Fixation Following Difficult Arthrodesis

Purpose

The purpose of this study is to highlight the advantages of locking plate fixation following difficult foot and ankle arthrodesis utilizing a multiplanar ring external fixator as the primary or revisional fixation device.

Methods

A retrospective chart review was performed on fifteen patients who had received rearfoot/ankle arthrodesis with fixation consisting of a multiplanar ring external fixator followed by the application of a locking plate. The patient population consisted of thirteen males and two females ranging in age from 64 to 9 years old. The authors evaluated the postoperative AOFAS scores.

Procedures

After removal of the multiplanar ring external fixator, the locking plate was placed percutaneously. For tibiotalocalcaneal (TTC) arthrodesis a small incision was made at the lateral aspect of the calcaneus. Blunt dissection was then carried proximally along the lateral aspect of the distal tibia and the plate was placed at the distal tibia and calcaneus. Care was taken to not violate the periosteum during dissection. Utilizing fluoroscopy, the plate was fixated with locking screws. A similar technique was performed for patients receiving isolated midfoot and rearfoot fusions. The patients were allowed to immediately weight-bear with the use of a CAM walker.

Results

Performing percutaneous locking plate fixation enabled the authors to remove the multiplanar ring external fixation an average of 2 weeks earlier than similar cases treated only with external fixation. The average AOFAS score postoperatively was 87. At the time of this poster presentation, no patients treated with this technique progressed to malunion or non-union. Two patients required plate removal after consolidation at the arthrodesis site and one patient developed sural neuritis, which was successfully treated with physical therapy and lidoderm patches.

AOFAS Score

Patients Required Plate Removal After Consolidation (15 total)

Patient Developed Sural Neuritis (15 total)

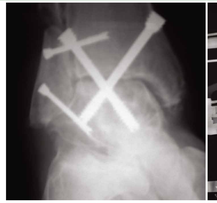

Figure 1: Failed Internal Fixation

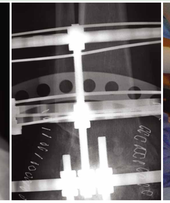

Figure 2: Revision with External Fixation

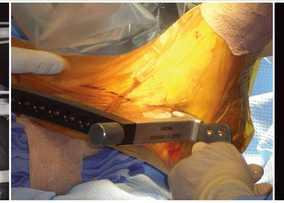

Figure 3: Percutaneous Locking Plate

Figure 4: Postoperative Xray

Literature Review

Locking plates have been shown to provide superior rigidity in complicated rearfoot fusions (T-T-C) when compared to other fixation techniques.[1,2,5] The complications of external fixation include the risk of pin track infection, higher non-union rate, and less accepted by patients. Certain patient conditions indicate the use of external fixation including soft-tissue injury, poor bone quality, compromised circulation, obesity, or infection.[3,4] The indications for locking plates have been documented as having four main principles including:

a. Compression principle for osteoporotic diaphyseal fractures;
b. Neutralization principle;
c. Bridging or locked internal fixator principle;
d. Combination principle for comminuted metaphyseal intra-articular fractures.[6]

The combination of locking plate technique after initial external fixation provides the patient benefits of both techniques.

Discussion

The use of locking plates has increased over the last several years. Locking plates have demonstrated excellent fixed-angle fixation and clear-cut results for fractures and non-unions.[5] The benefits to using locking plates in osteopenic bone to achieve rigid fixation and lower the chance of non-union has been greatly documented.[1] Utilizing the technique of percutaneous locking plate fixation following arthrodeses with a multiplanar ring external fixator decreases the risk of non-union and malunion while increasing patient comfort by removing the external fixator. By incorporating this technique in high-risk fusions the surgeon may increase his/her success rate of such treatments while minimizing peri-operative complications.

References:

1. Ahmad J, Eslam Pour A, Raikin S. *The Modified Use of a Proximal Humeral Locking Plate for Tibiotalocalcaneal Arthrodesis.* Foot Ankle Int. 28(9):977-983, 2007.
2. Chodos MD, Parks BG, Schon LC, Guyton GP, Campbell JT. *Blade Plate Compared with Locking Plate for Tibiotalocalcaneal Arthrodesis: A Cadaver Study.* Foot Ankle Int. 29(2): 219-224, 2008.
3. Fragomen AT, Meyers KN, Davis N, Shu H, Wright T, Rozbruch SR. *A Biomechanical Comparison of Micromotion After Ankle Fusion Using 2 Fixation Techniques: Intramedullary Arthrodesis Nail or Ilizarov External Fixator.* Foot Ankle Int. 29(3): 334-341, 2008.
4. Mueckley TM, Eichorn S, Oldenburg, GV, Speitling A, DiCicco III JD, Hofmann G, Buhren V. *Biomechanical Evaluation of Primary Stiffness of Tibiotalar Arthrodesis with an Intramedullary Compression Nail and Four Other Fixation Devices.* Foot Ankle Int. 27(10): 814-820, 2006
5. O'neil PJ, Logel KJ, Parks BG, Schon LC. *Comparison of Locking Plate and Intramedullary Fixation for Tibiotalocalcaneal Arthrodesis.* Foot Ankle Int. 29(6):581-586, 2008.
6. Smith WR, Ziran BH, Anglen JO, Stabel PF. *Locking Plates: Tips and Tricks.* J Bone Joint Surg Am (89):2298-2307, 2007.

Key Contributors:
Edgardo R. Rodriguez, DPM Clinical Instructor
Director: Chicago Foot & Ankle Deformity Correction Center

Shawn Hatfield DPM PGY-3

Affiliation(s): St. Joseph Hospital/North Chicago DVAMC PM&S-36 Residency Program

Category: Rearfoot & Ankle Reconstruction
Type of Submission: Institution
Format: Scientific

Presented: American College of Foot & Ankle Surgeons Scientific National Meeting 2009

Resurrection Health Care

Podiatric Surgical Residency Program
St. Joseph Hospital/North Chicago DVAMC PM&S-36
Program Director
Frank W. Zappa, DPM

©2009 Resurrection Health Care. All Rights Reserved.